

ROLE OF CORONARY COMPUTED TOMOGRAPHY ANGIOGRAPHY IN DIAGNOSIS OF STABLE CHEST PAIN

SABAH HUSSEN ALI TERFASS
(MBChB ,M.SC)
Diagnostic and Therapeutic Radiology
Department
Collage Of Medical Sciences and
Technology Tripoli
TRIPOLI, LIBYA
Sterfass@gmail.com

ESMAIL R IBRAHIM HASSAN
(M.SC)
Diagnostic and Therapeutic Radiology
Department
Collage Of Medical Sciences and
Technology Tripoli
TRIPOLI, LIBYA
Esmail_hassan@yahoo.com

OMAR ALMOKHTAR TERFASS
High diploma in radiology
Diagnostic and Therapeutic Radiology
Department
Collage Of Medical Sciences and
Technology Tripoli
TRIPOLI, LIBYA
oalmoktar@gmail.com

Abstract— Chest pain is often the herald of cardiovascular disease and is one of the most common diagnostic challenges encountered by practicing clinicians. Cardiovascular disease remains a leading cause of morbidity and mortality worldwide, despite advances in medical and procedural therapies.

Coronary Cardiac computed tomography angiography is a radiographic test that allows visualization the presence and severity of coronary artery stenosis. It is an anatomical test that can be used in patients with stable chest pain.

This study aims to find the role of CCTA in diagnosis of non acute chest pain. So **40** case study of patient complaining of non acute chest pain were conducted in Tripoli University Hospital by primary investigation and evaluated by **Coronary computed tomography angiography technique** (CCTA).

The result shows that CCTA is an excellent non-invasive diagnostic modality that can be utilized to study in detail the coronary anatomy. It can sometimes supplant traditional invasive coronary angiography, especially in patients in whom the need for coronary intervention is felt to be unlikely. It's also a good tool to detect the exact place of coronary arteries blockage and narrowing in excellent way.

Keywords— *Coronary computed tomography angiography technique (CCTA), Coronary artery disease (CAD).*

1. Introduction

Chest Pain Is Often the Herald Of Cardiovascular Disease And Is One Of The Most Common Diagnostic

Challenges Encountered By Practicing Clinicians. Cardiovascular Disease Remains A Leading Cause Of Morbidity And Mortality Worldwide, Despite Advances In Medical And Procedural Therapies. Coronary Artery Disease (CAD) Is An Important Subset Of Cardiovascular Disease That Requires Timely, Accurate, And Cost-Effective Diagnosis. CCTA uses an injection of iodine-containing contrast material and CT scanning to examine the arteries that supply blood to the heart and determine whether they have been narrowed.

CCTA can provide important information about the presence and extent of plaque in the coronary arteries. Apart from identifying coronary artery narrowing as the cause of chest discomfort, it can also detect other possible causes of symptoms, such as a collapsed lung, blood clot in the vessels leading to the lungs, or aortic abnormalities. (1)

2. Material and Methodology:

This study based on statistical study (Case study) of **40** stable ischemic heart disease cases, during **three months** period in **diagnostic radiology departments** at **Tripoli university Hospital** presented with history of chest pain. The cases were diagnosed primary by ECG and laboratory tests, and then referred for more evaluation by CCTA technique.

The Techniques used includes Lateral and AP scout covering the AP Scanogram 120kVp/50mA Position the patient for AP scanogram heart and coronaries.

Lat Scanogram 120kVp/100mAto acquires AP and lateral scanograms heart is at the center of the scan field. The injection rate should be Set the ^{SURE}Start trigger at 180 HU Single Phase Contrast with Saline and biphasic injection protocol to show specific parts of the heart.

3. Results:

40 cases of patient complaining of non emergency chest pain have been evaluated in **diagnostic radiology departments** at **Tripoli university Hospital** in period of three months and the result were as following:

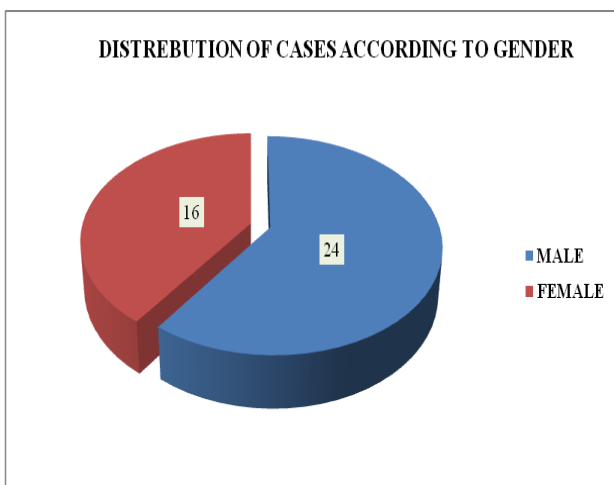


Fig (1) show distribution of cases according to sex

It is clear that male attend the CCTA more than female with 24 male cases and 16 female.

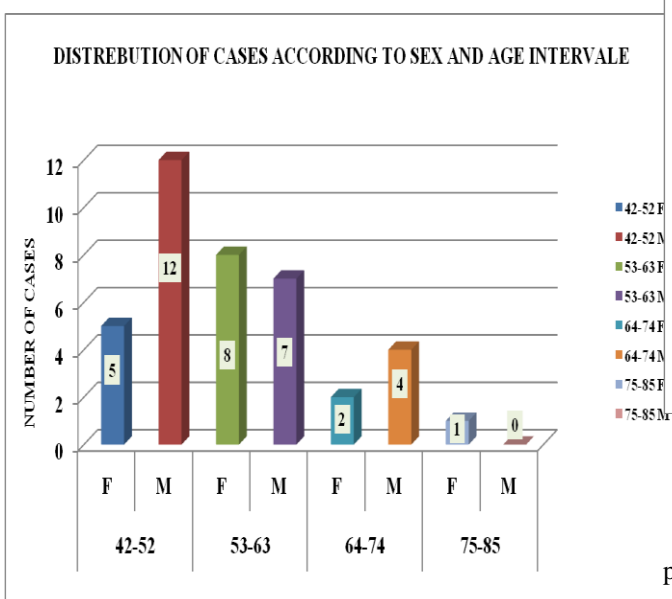


Fig (2) show distribution of cases according to sex and age interval

It has been found that the most age interval affected with coronary arteries disease is between 42-52 with 12 male case and 5 female cases then the incidence almost equal in the next age interval 53-63 due to menopause period that make female in equal incidence with male in having CAD, then the incidence decline due to the complication of the CAD.

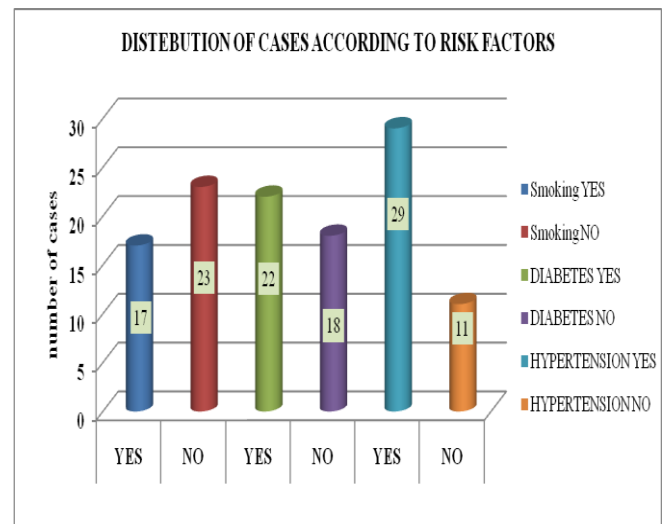


Fig (3) show distribution of cases according to risk factor

The figure shows that 17 cases were smoker, 22 diabetic and 29 were hypertensive.

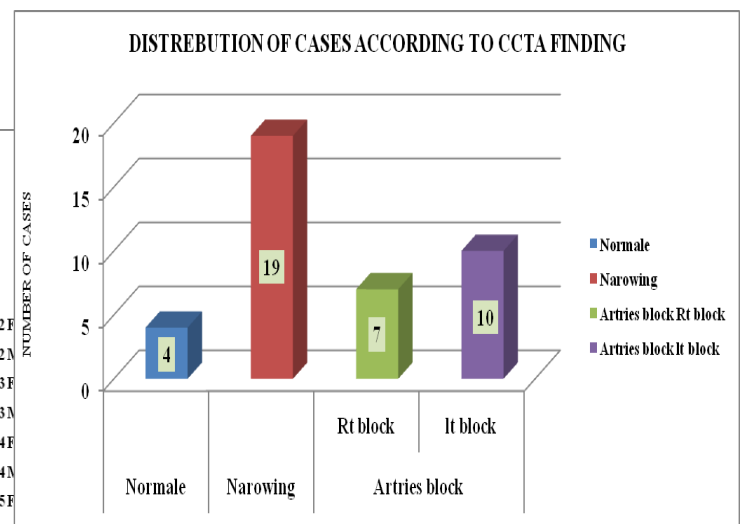


Fig (4) show distribution of cases according to CCTA finding

The above figure show that from 40 cases that take this procedure, the results were as following, 4 cases were normal and 19 cases were having narrowing in the coronary arteries

and **17** cases have blockage **7** of them were in the right coronary arteries and **10** cases the blockage were in the left coronary arteries.

4. Discussion:

most age interval affected with coronary arteries disease is between **42-52** with **12 male** case and **5** female cases then the incidence almost equal in the next age interval 53-63 due to menopause period that make female in equal incidence with male in having CAD, then the incidence decline due to the complication of the CAD.

From **40** cases that take this procedure **4** cases were normal , 19 cases were having narrowing in the coronary arteries and **17** cases have blockage **7** of them were in the right coronary arteries and **10** cases the blockage were in the left coronary arteries.

CCTA has generated interest since it may rule out obstructive CAD in a noninvasive procedure with a low risk of adverse events.

5. Conclusions:

The study of **40** cases shows that, CCTA is an accurate, noninvasive alternative to invasive coronary angiography (ICA) in patients with stable chest pain and intermediate pretest probability for obstructive CAD.

It's also a good tool to detect the exact place of coronary arteries blockage and narrowing in excellent way, beside it identifies patients who are appropriate candidates for coronary revascularization. However CCTA enables coronary revascularization during the same procedure.

6. Acknowledge

The authors acknowledge the diagnostic radiology departments staff at Tripoli university Hospital for provide us with counseling and data.

REFERENCES:

1. Neurauter E, Leschka S, Wildermuth S, Ehl NF, Joerg L, Rickli H, Maeder MT. Use of coronary computed tomography angiography in clinical practice - single

centre experience in Switzerland in light of current recommendations based on pretest probability considerations. *Swiss Med Wkly.* 2019 Jan 14;149:w20010.

2. Bettencourt N. Management of patients after computed tomography coronary angiography: Evidence and room for improvement. *Rev Port Cardiol (Engl Ed).* 2019 Jan;38(1):51-52.
3. Bellinge JW, Majeed K, Carr SS, Jones J, Hong I, Francis RJ, Schultz CJ. Coronary artery 18F-NaF PET analysis with the use of an elastic motion correction software. *J Nucl Cardiol.* 2020 Jun;27(3):952-961.
4. Gottlieb I, Bettencourt MS, Rochitte CE, Cavalcante JL. Coronary Computed Tomography Angiography Takes the Center Stage and Here is Why. *Arq Bras Cardiol.* 2019 Jan;112(1):104-106.